

Imaging For the Transseptal Fluoroscopy, ICE, TEE and CT

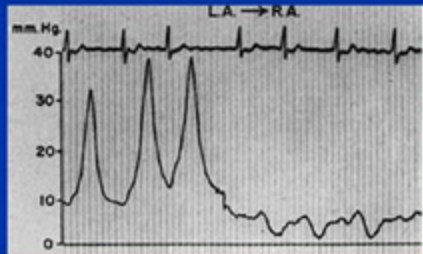
Samir R. Kapadia, MD

Professor of Medicine
Director, Cardiac Catheterization Laboratories
Cleveland Clinic, USA

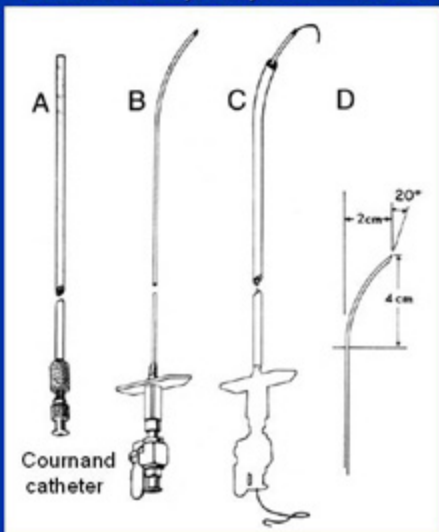
History of LA Catheterization

- Dr. Morrow
 - Transbronchial
 - Direct suprasternal puncture
- Dr John Ross was sent from Hopkins to National Heart Institute by Dr. Blalock to train under Dr. Morrow
- TSP Catheter used with Dr. Morrow and Dr. Braunwald

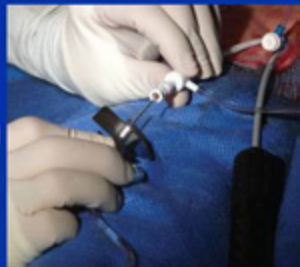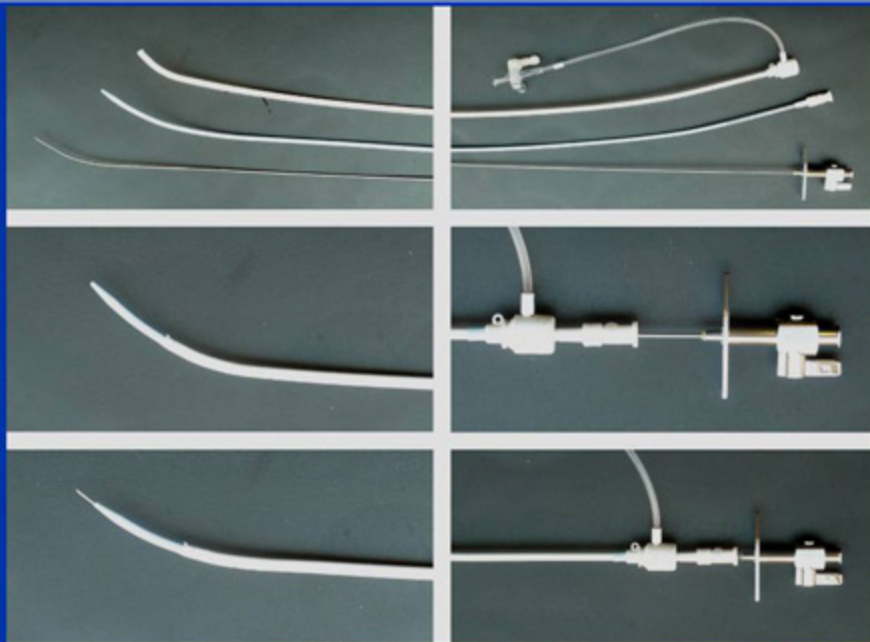
First Patient



Catheter Produced by
John Ross, JR, MD - 1957



Current Assembly



TSP Complications are not Trivial

Table 1. Percutaneous Balloon Mitral Valvuloplasty: Examples of Incidence of Tamponade in 1 Type of Structural Heart Disease Intervention

Author(s) (Ref. #)	No. of Patients	Death (%)	Tamponade (%)
Vahanian et al. (37)	200	0	0.5
Ruiz et al. (38)	285	1.1	2.1
Hung et al. (39)	219	0.5	0
Cohen et al. (34)	146	1.4	4.1
Rothlisberger et al. (40)	235	0.8	1.3
NHLBI (35)	738	1.0	4.0
Feldman (41)	290	1.4	1.4
Arora et al. (42)	600	1.0	1.3
Joseph et al. (43)	903	0.9	1.1
Bozat et al. (44)*	243	0.0	1.5
Varma et al. (45)	1,388	0.2	0.6

*Comparison of percutaneous balloon mitral valvuloplasty in unanticoagulated (n = 109) and anticoagulated patients (n = 134). Tamponade occurred only in the anticoagulated patients. Adapted, with permission, from Glazier and Turi (36).

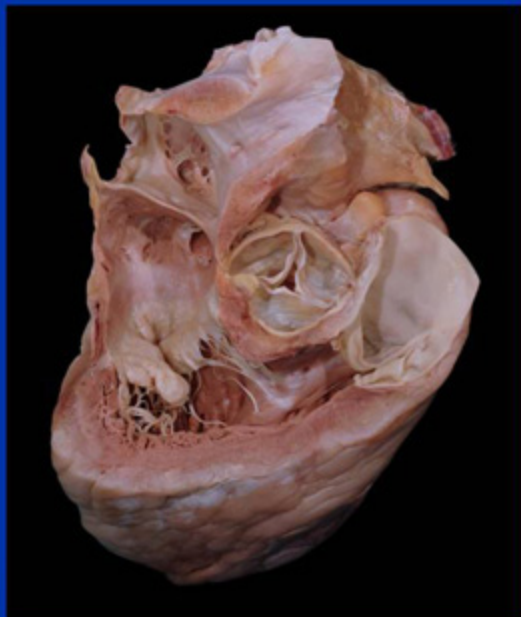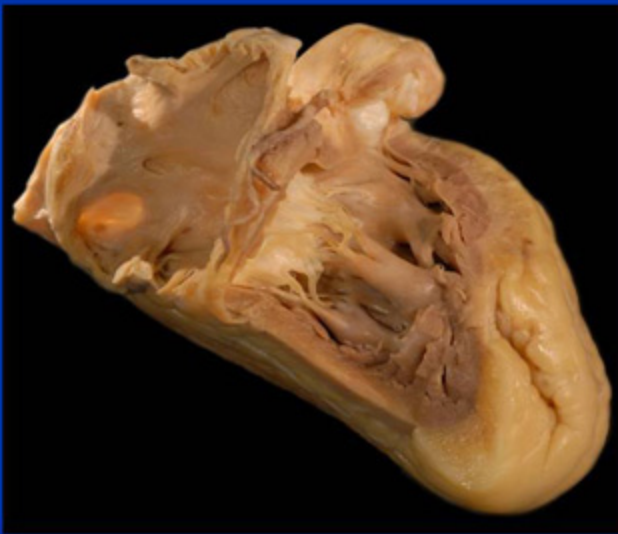High Risk TSP

- Repeat transseptal catheterization
- Atrial septal aneurysm
- Hypertrophied interatrial septum
- Surgically repaired septum
- Device closure of ASD and PFO
- Abnormal rotation of the cardiac axis
- Distorted anatomy of interatrial septum due to congenital heart disease
- Severe scoliosis

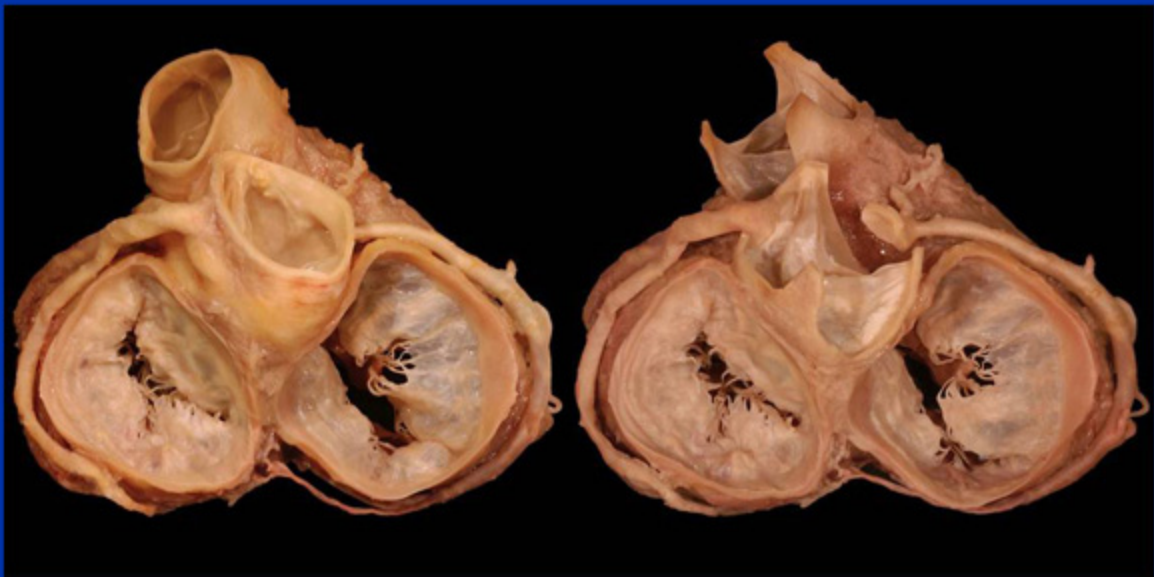
Understanding the Anatomy

- Cardiac Anatomy
- Fluoro-anatomy and Landmarks
- Echo imaging (TEE and ICE)
- Planning with CT

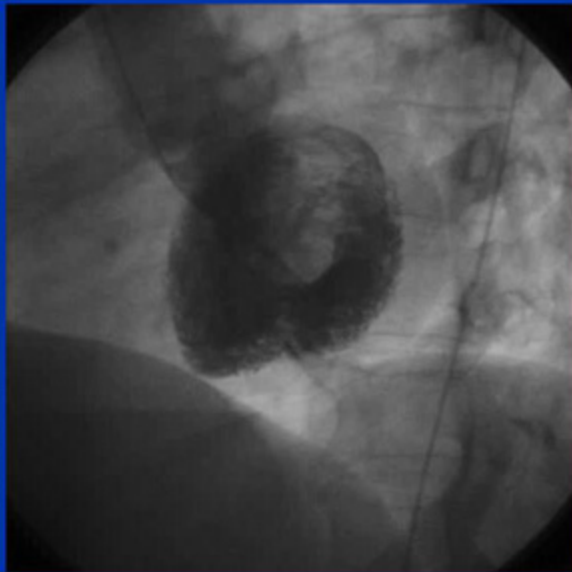
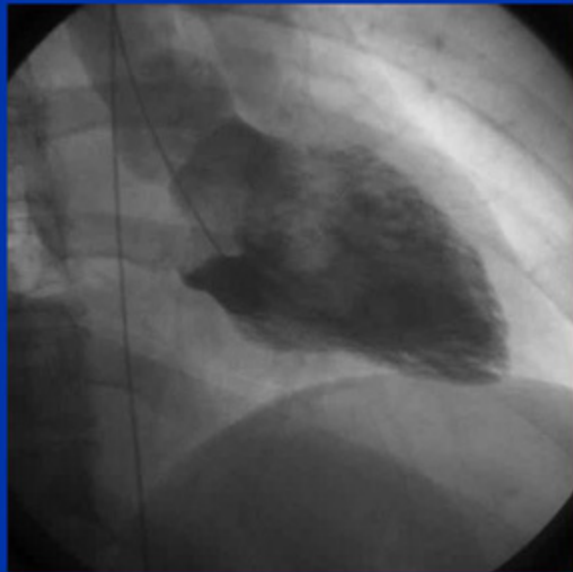
Septal Anatomy

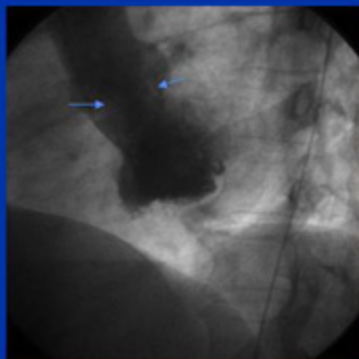
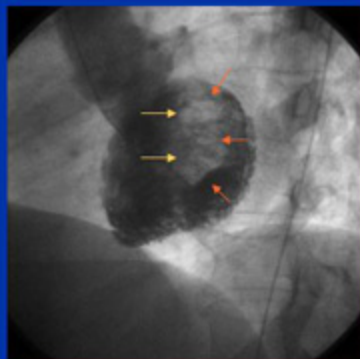
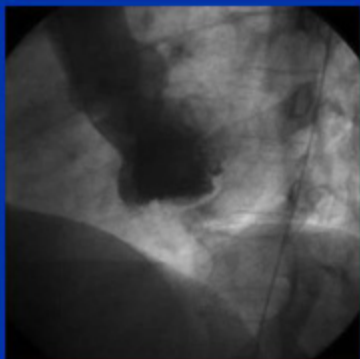
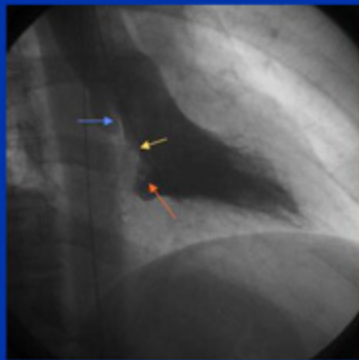
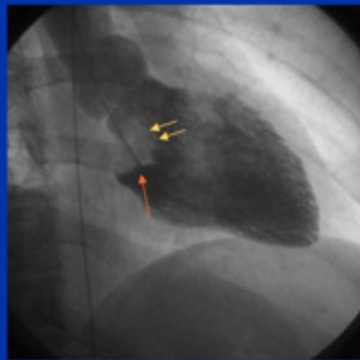
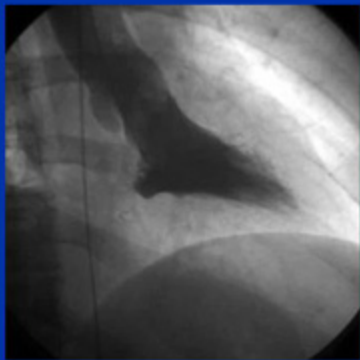


Aortic – Mitral and Septal Relations

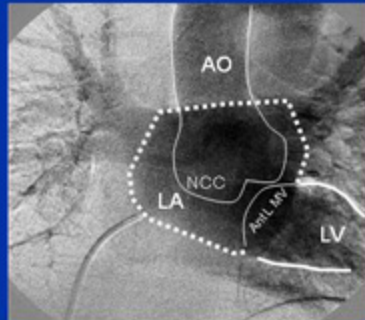
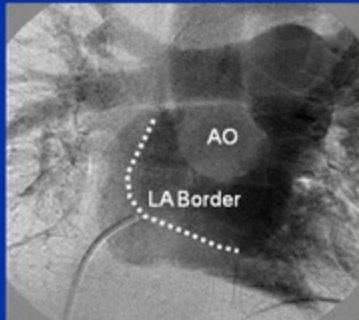
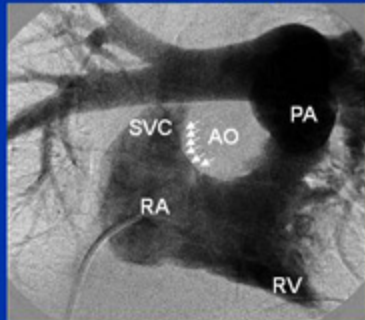


Flouro Anatomy: Left Ventricle

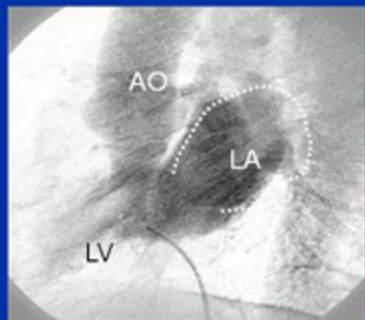
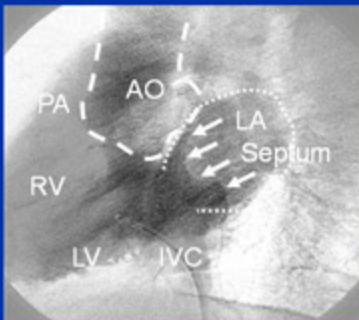
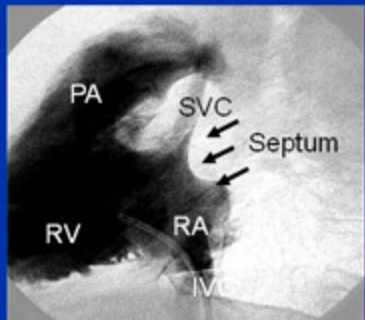




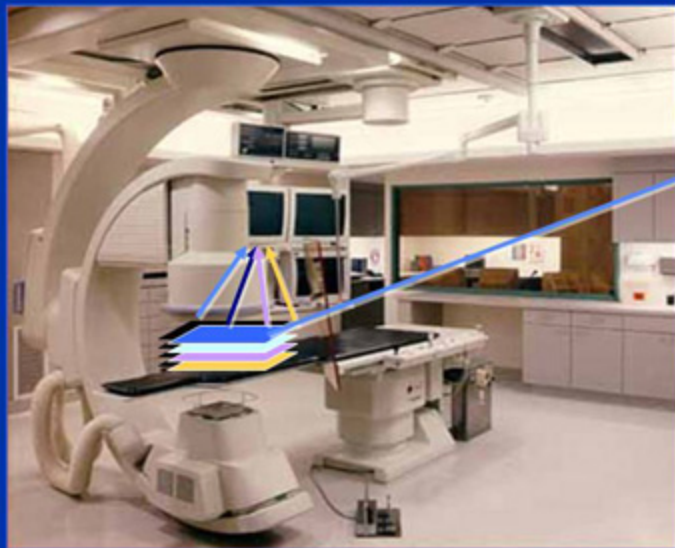Flouro Anatomy: AP



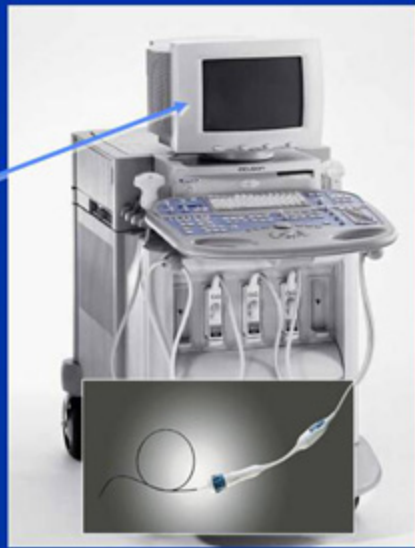Flouro Anatomy: LATERAL

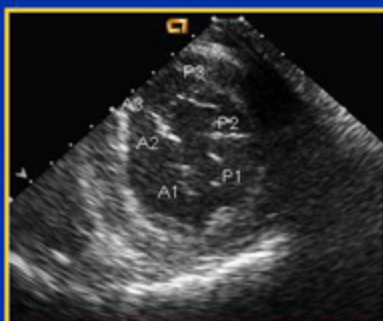
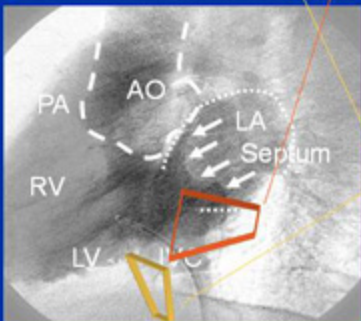
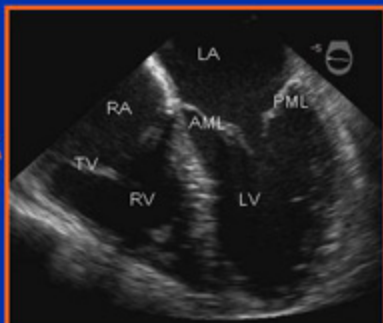
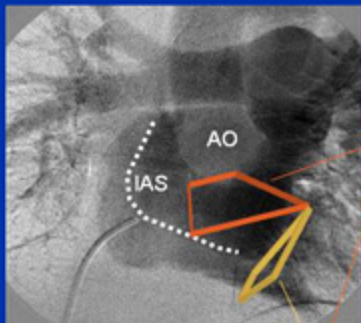


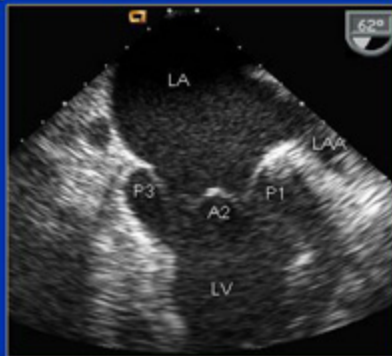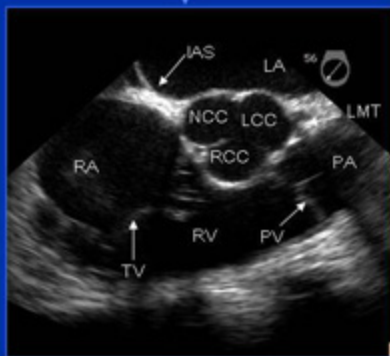
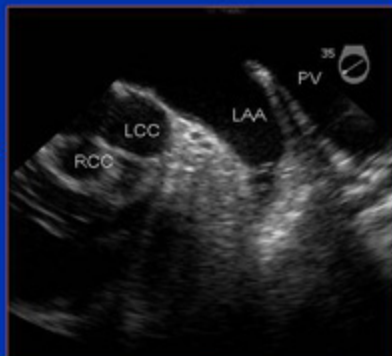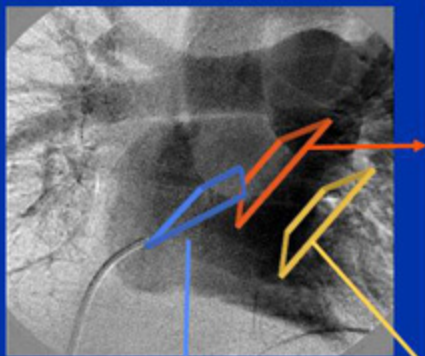
FLUOROSCOPY

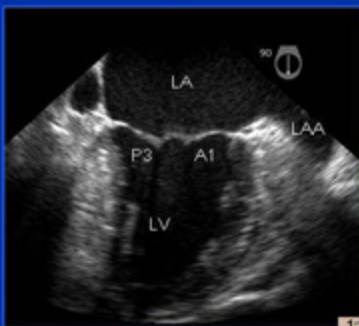
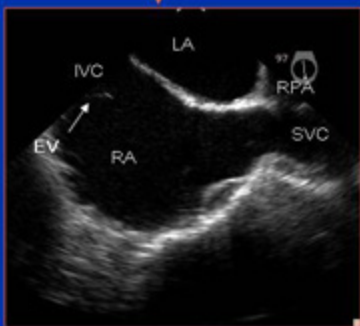
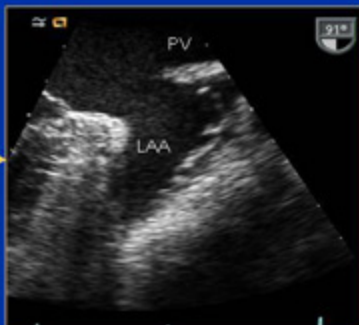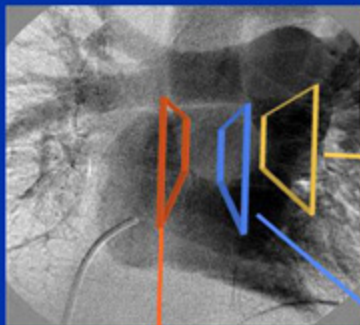


ECHO

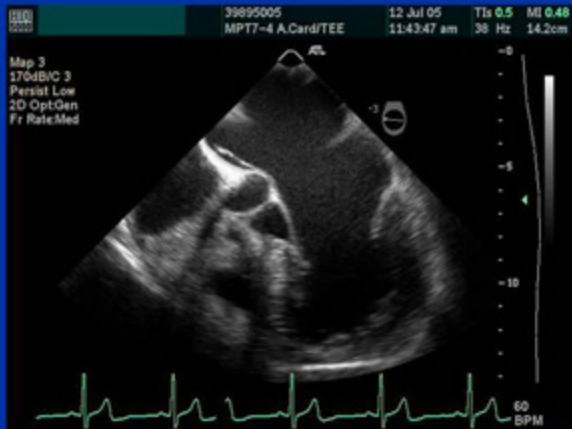
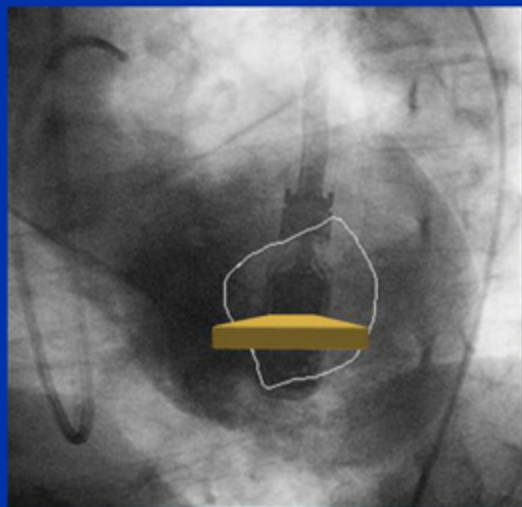




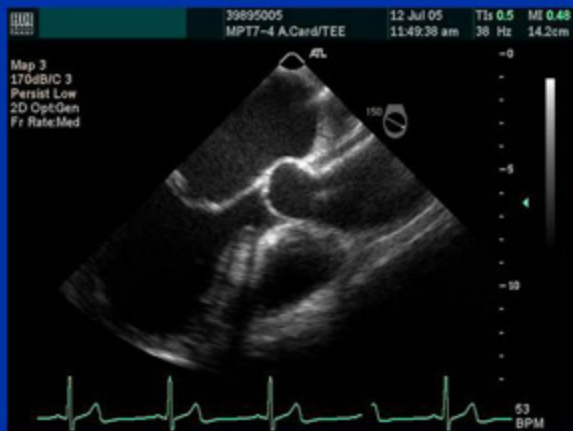
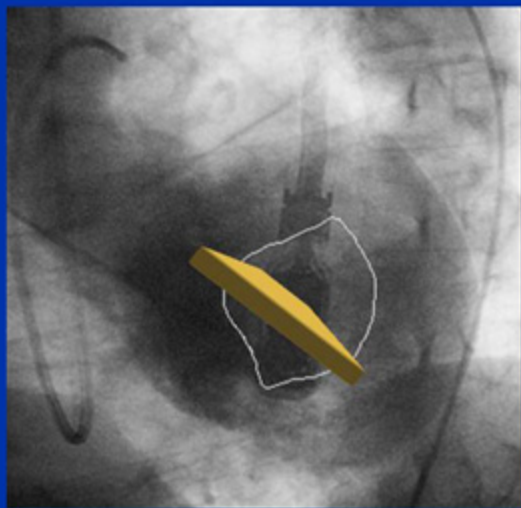




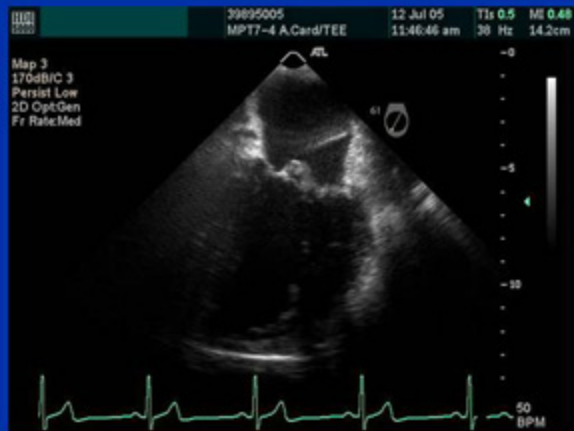
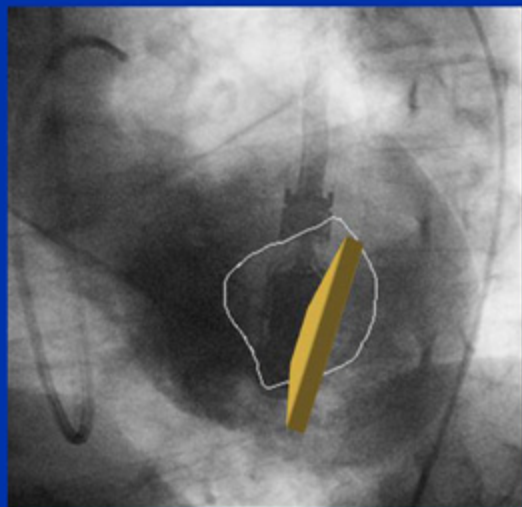
TEE and Fluoro Anatomy: 4 chamber



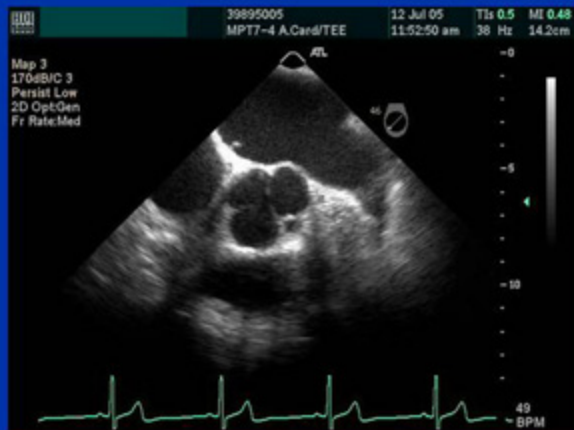
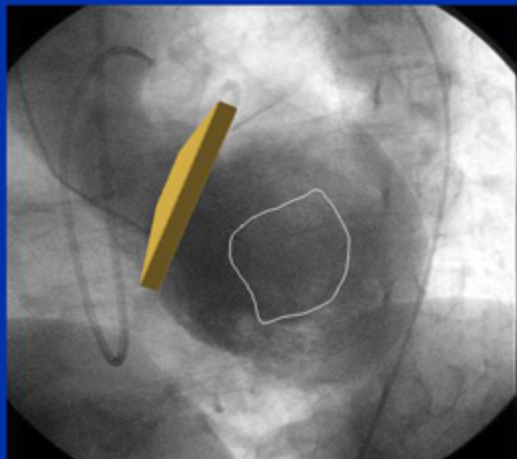
TEE and Fluoro Anatomy: Long axis



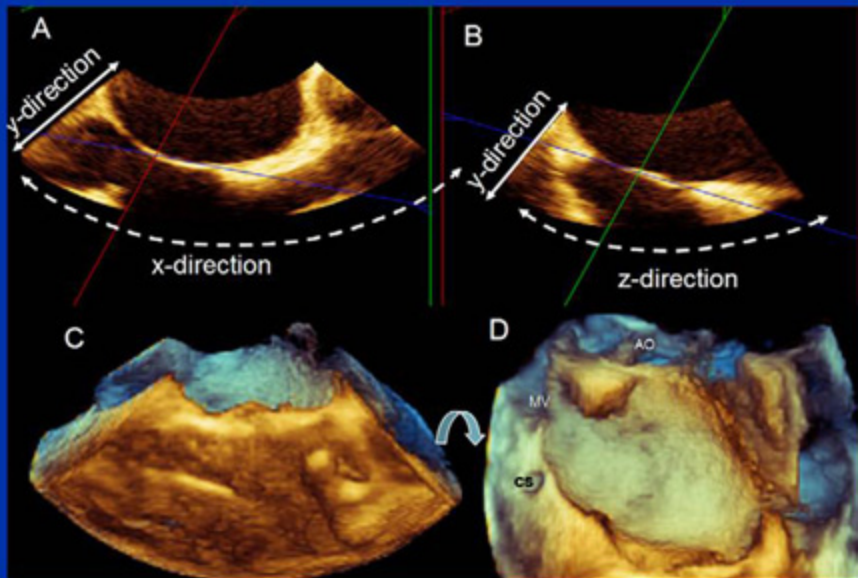
TEE and Fluoro Anatomy: Commissural



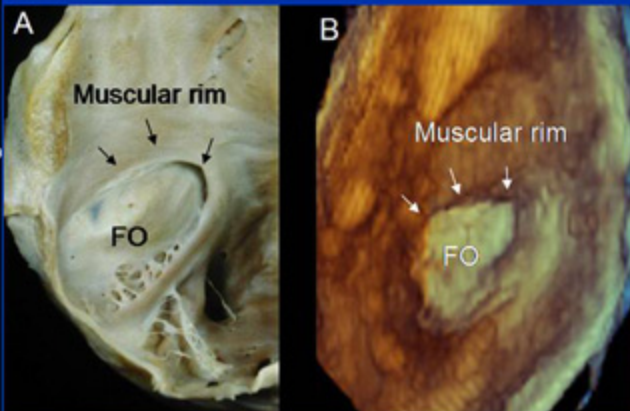
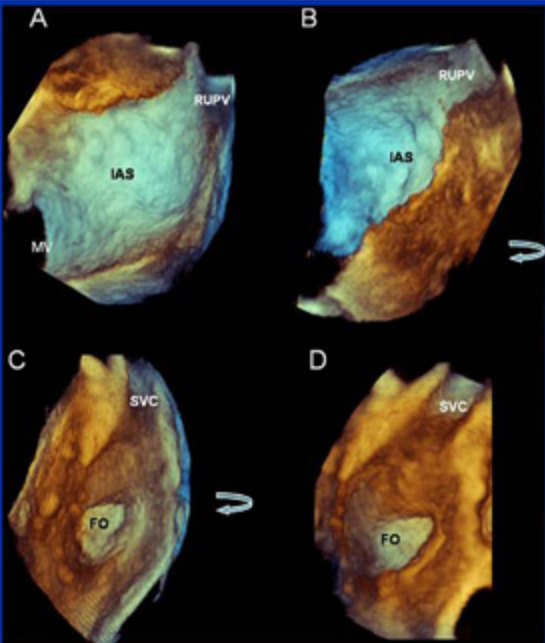
TEE and Fluoro Anatomy: Aortic Short Axis



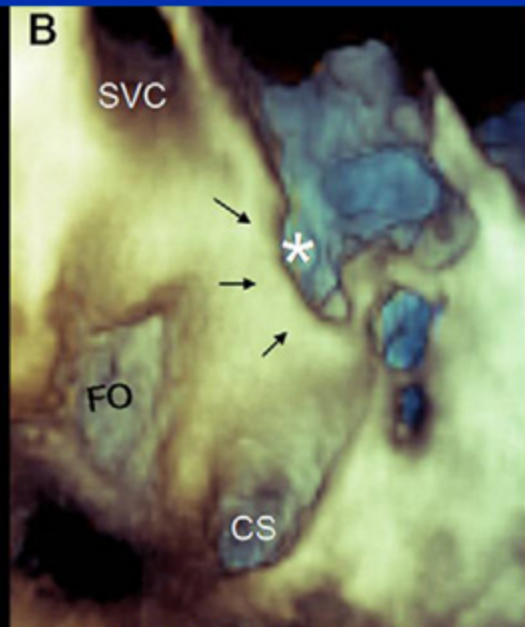
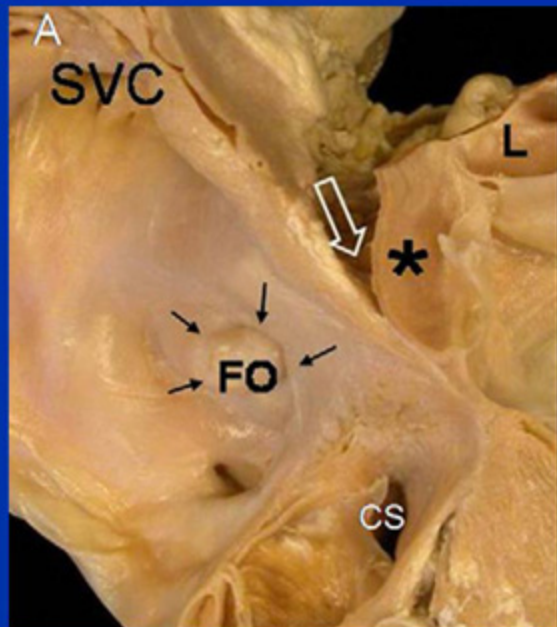
3D TEE



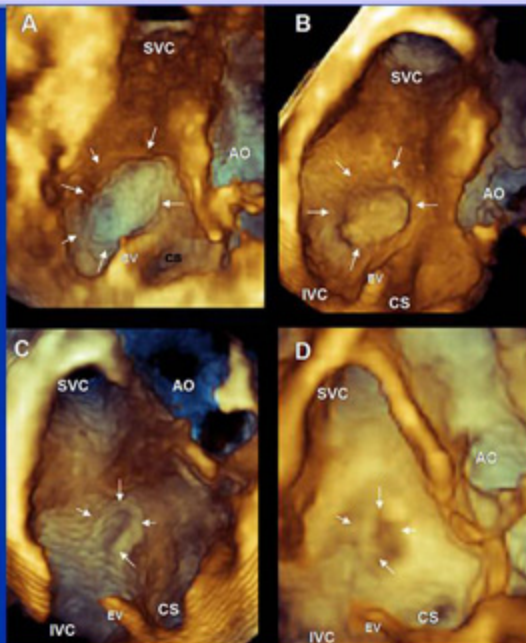
Left and Right Atrial Perspective



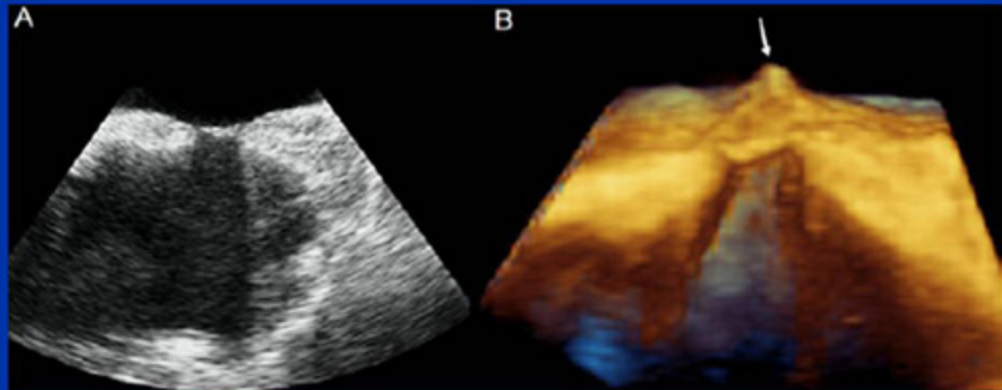
Right Atrial Perspective

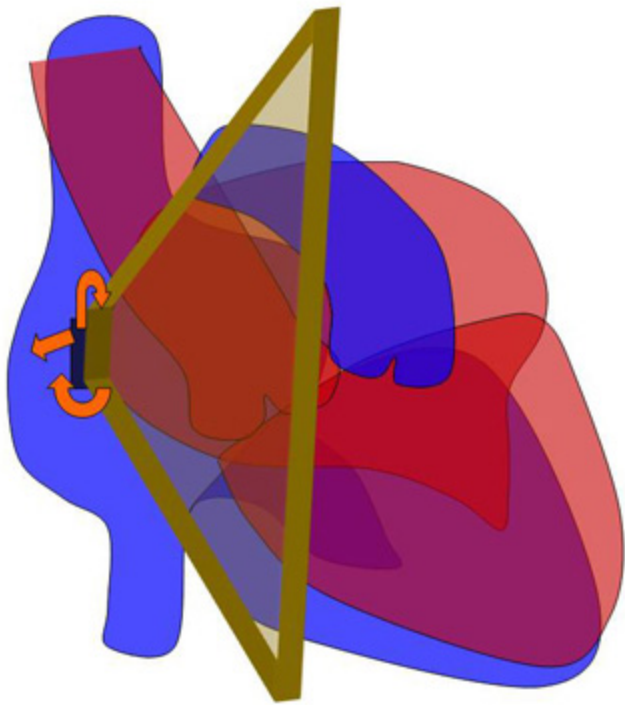


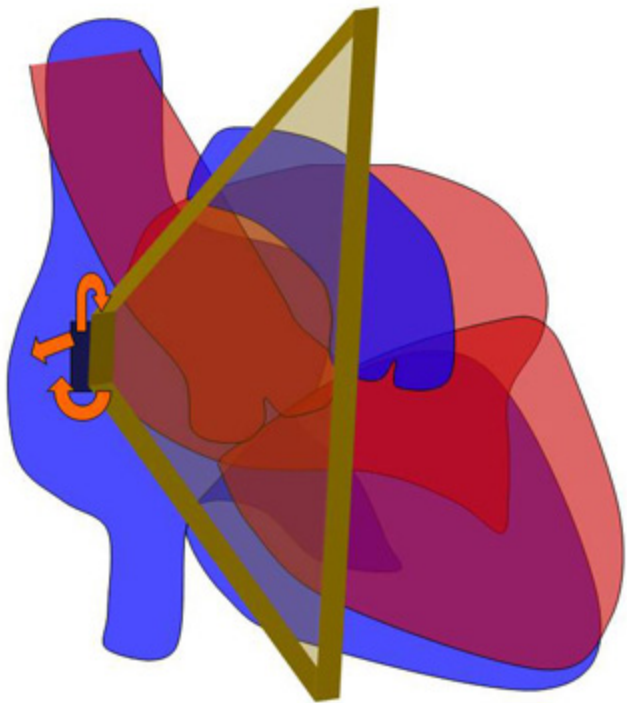
Different Sizes of Fossa Ovalis

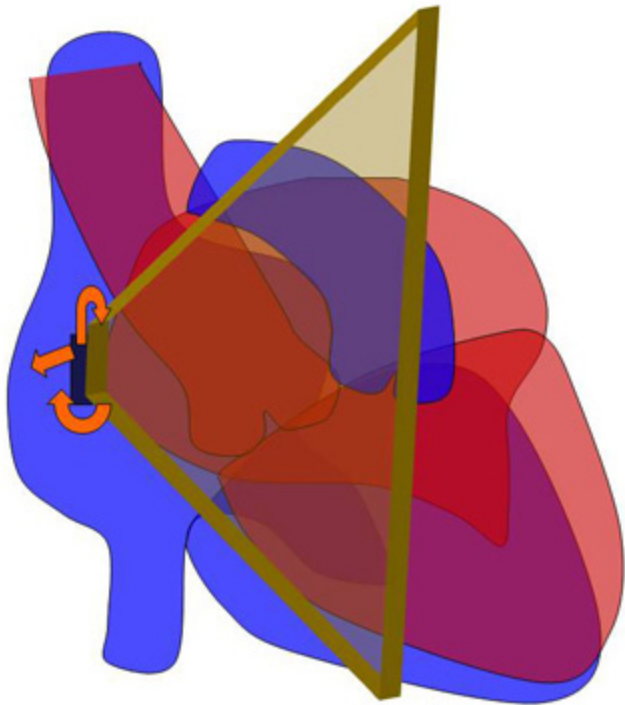


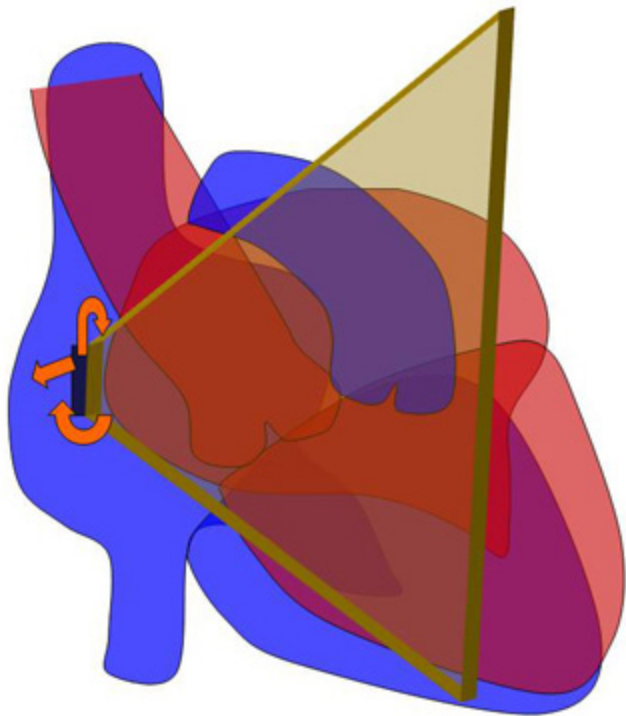
Tenting

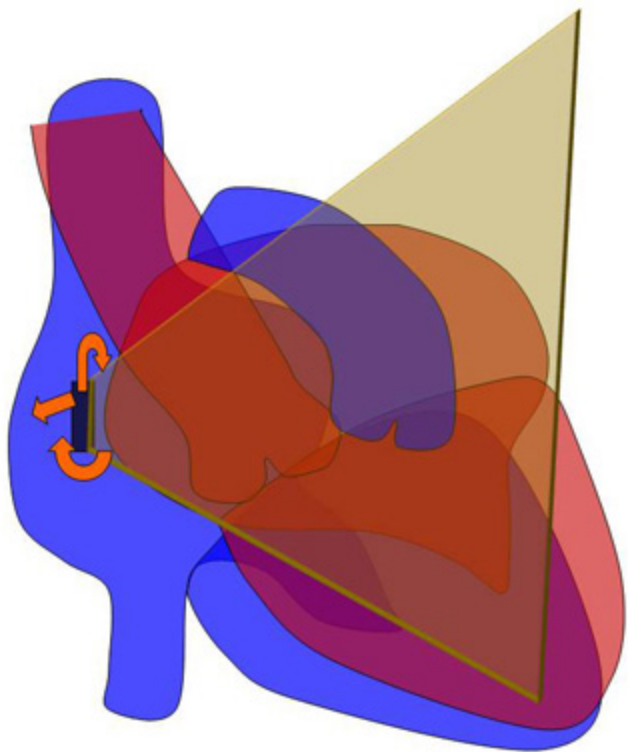


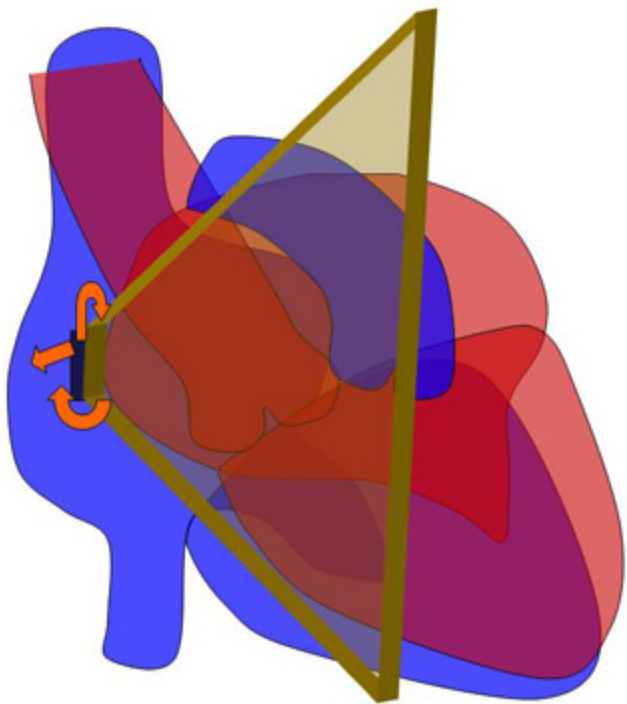


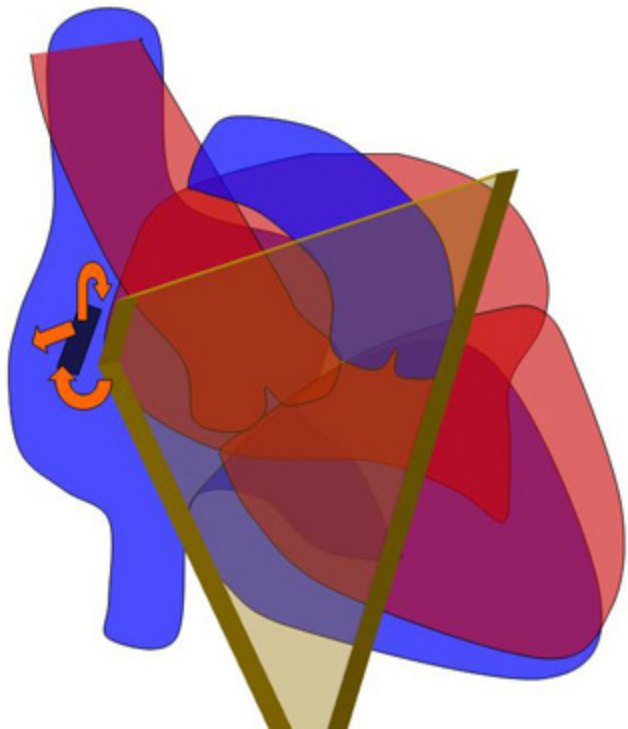


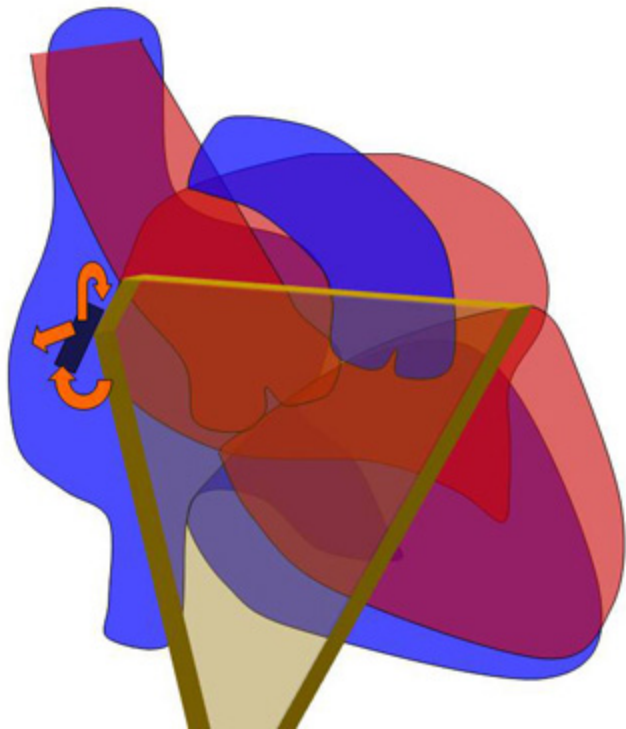


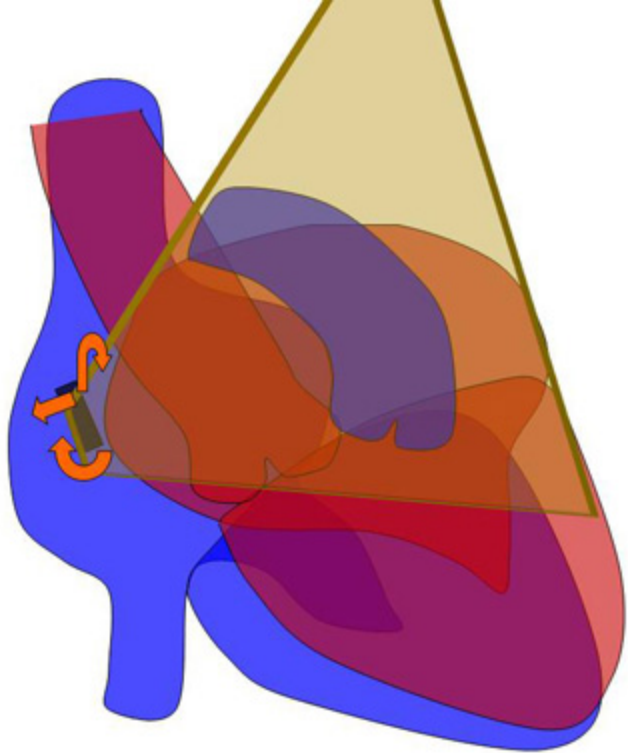


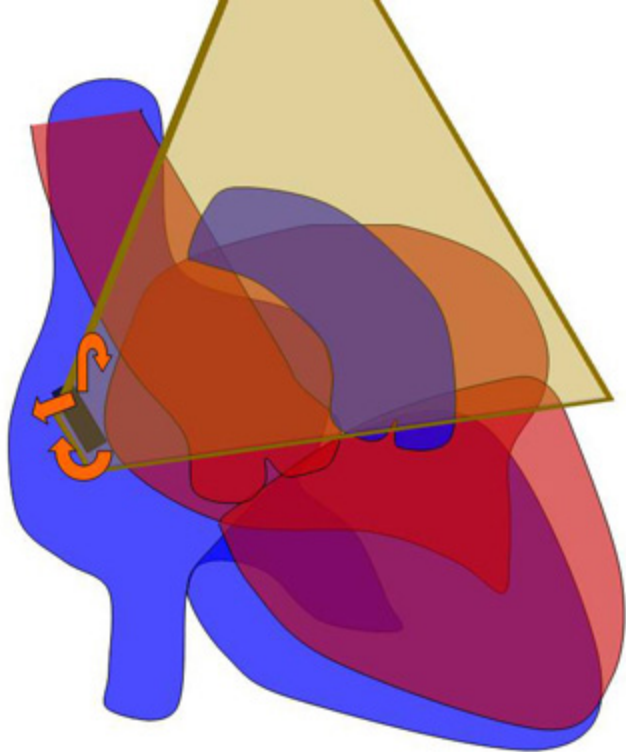


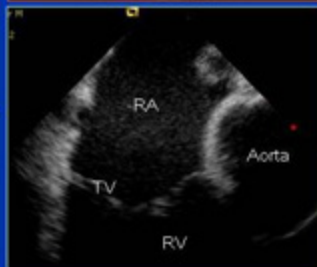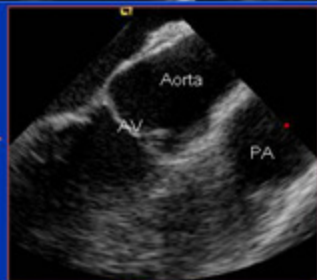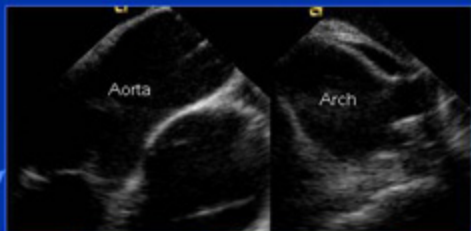
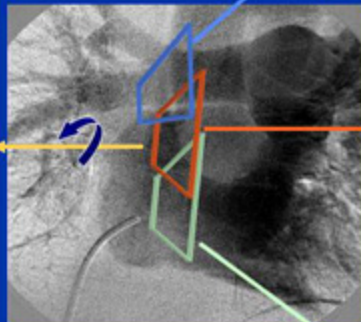


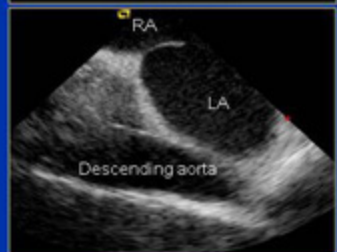
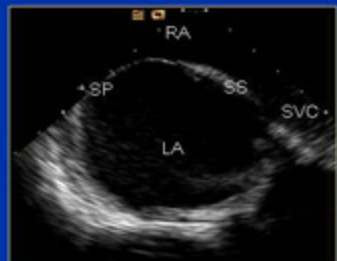
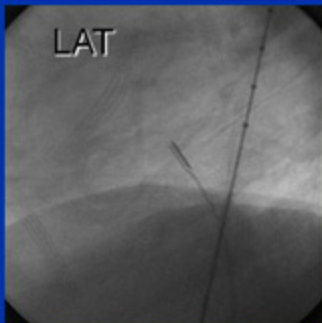
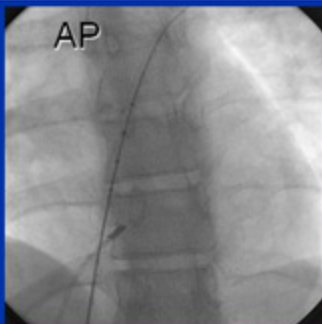
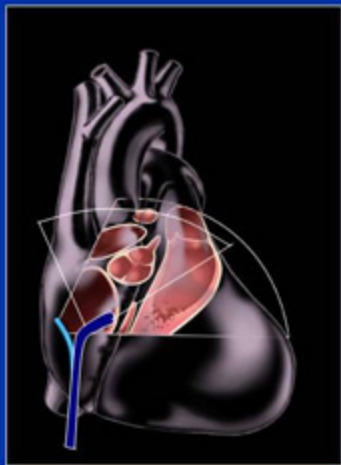








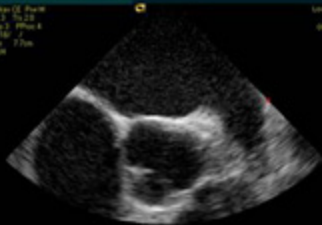Anterior Horizontal View



Ujg- Cleveland Clinic Adult Cath Lab

Acquisition (2) FourW
MC 1.2 To 2.2
Comp 3 Phase 4
Cath 160
Wire 7.7cm
Pacer

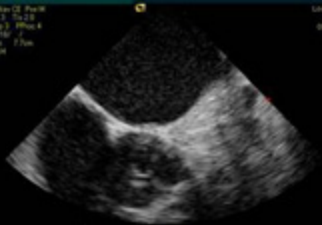Loop 27 / 50
07.03.2014
08.54.2014



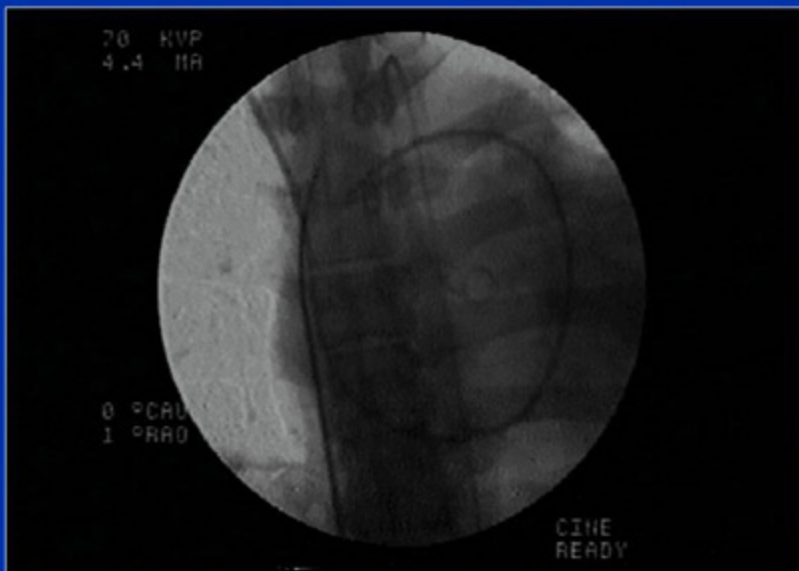
Ujg- Cleveland Clinic Adult Cath Lab

Acquisition (2) FourW
MC 1.2 To 2.2
Comp 3 Phase 4
Cath 160
Wire 7.7cm
Pacer

Loop 27 / 50
07.03.2014
08.54.2014



Trans-septal Puncture

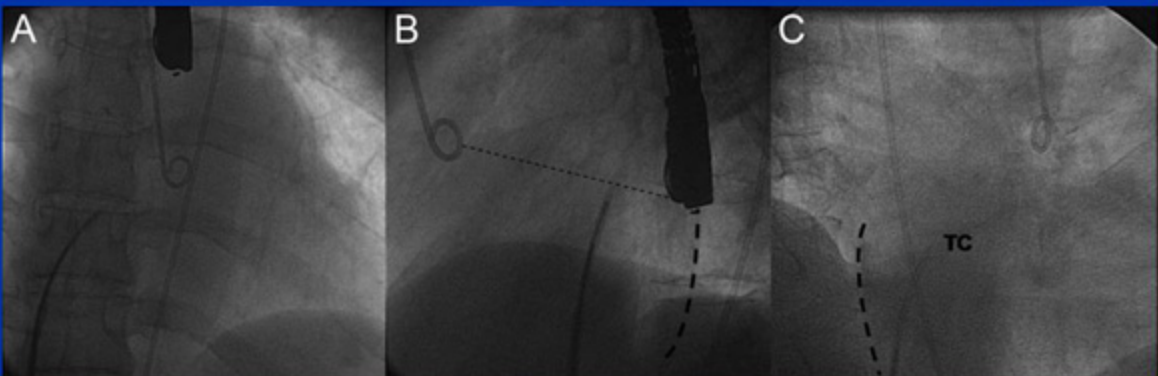


Fluoroscopic Landmarks

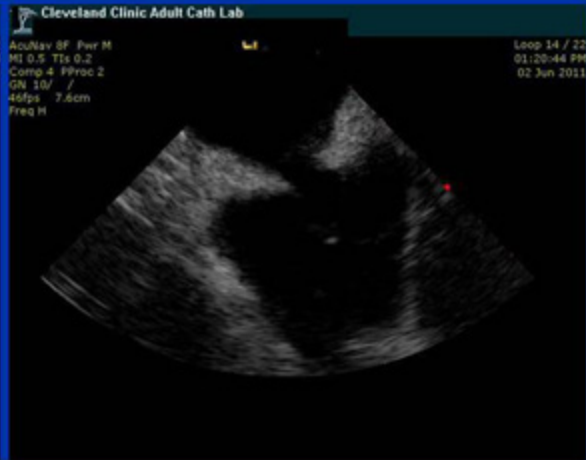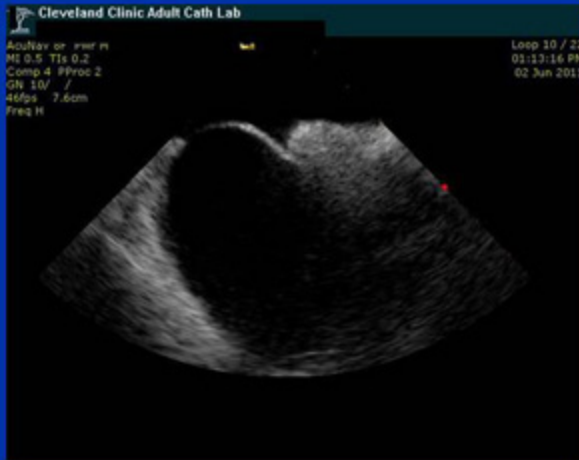AP

LAT

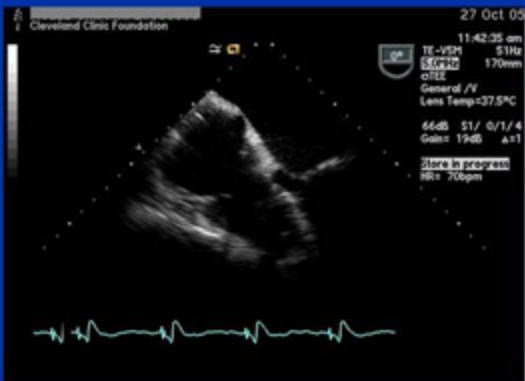
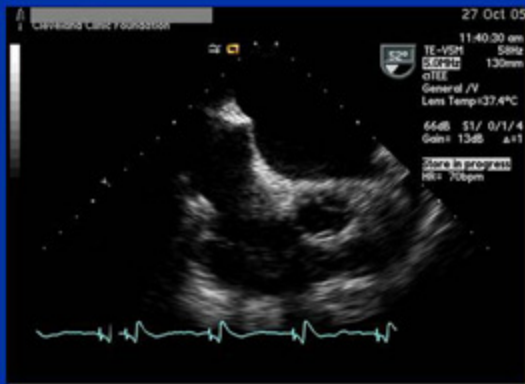
RAO



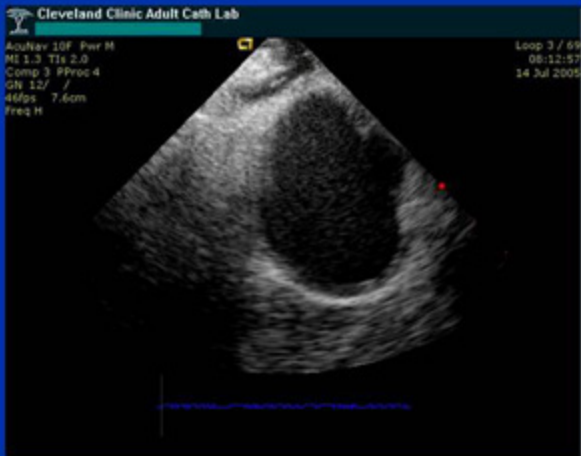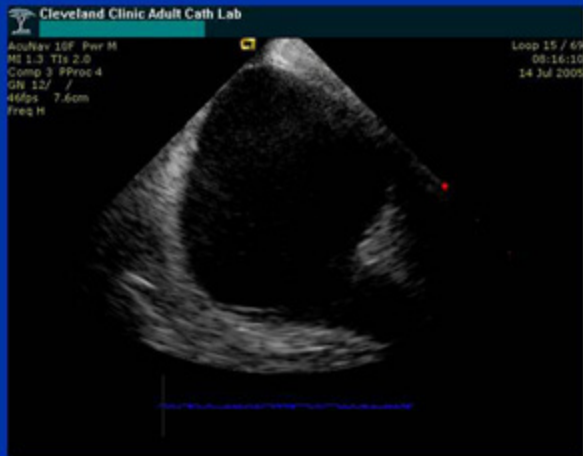ICE Imaging (Floppy Septum)



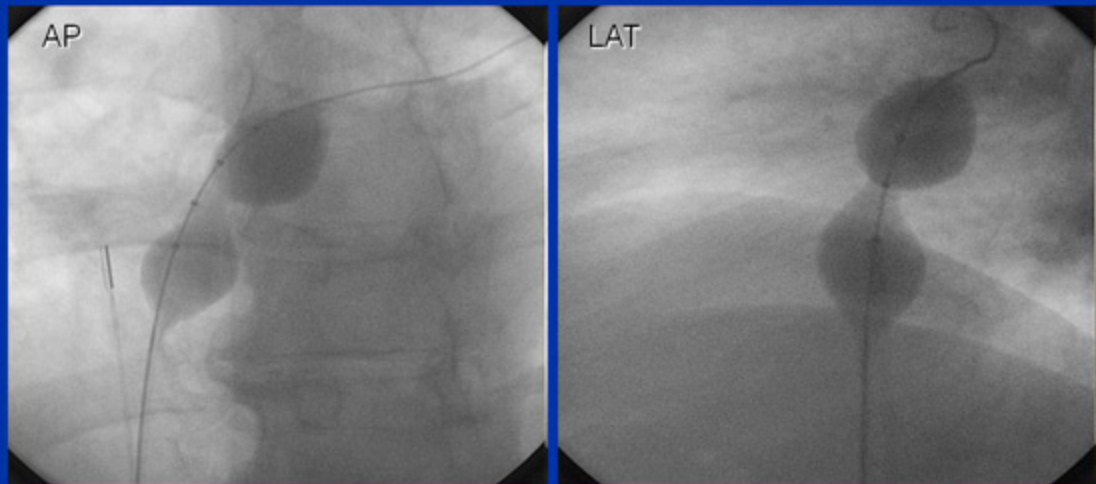
Trans-Septal Puncture Site on TEE



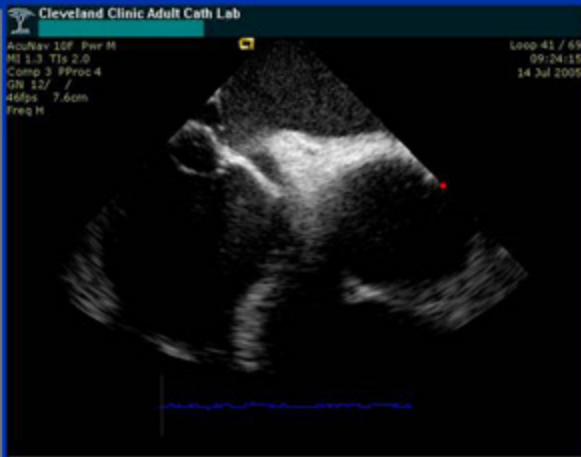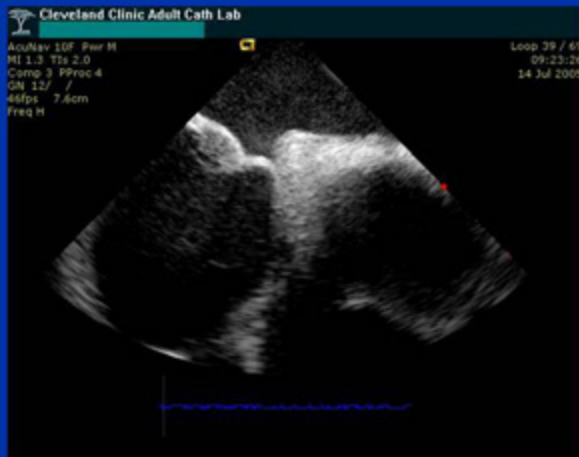Hypertrophied Septum Secundum and a Long Tunnel



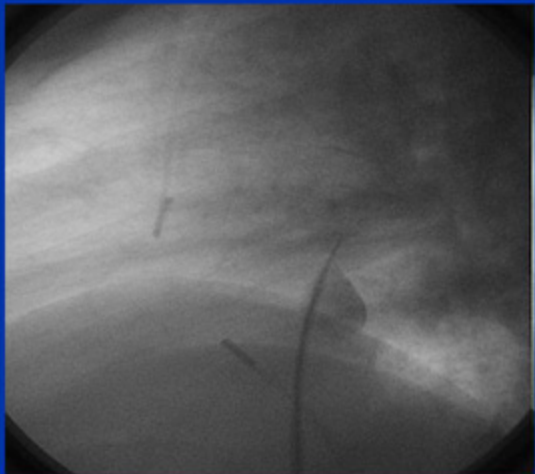
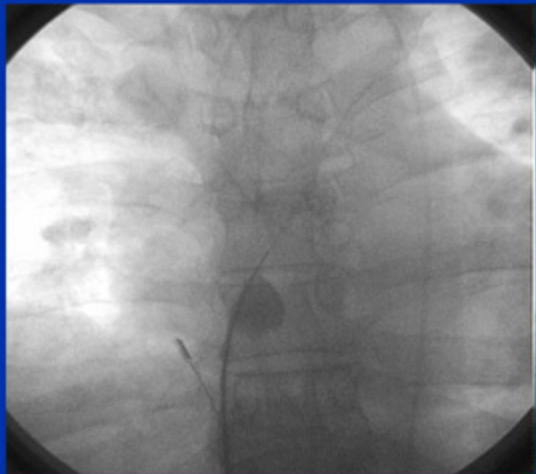
Tunnel



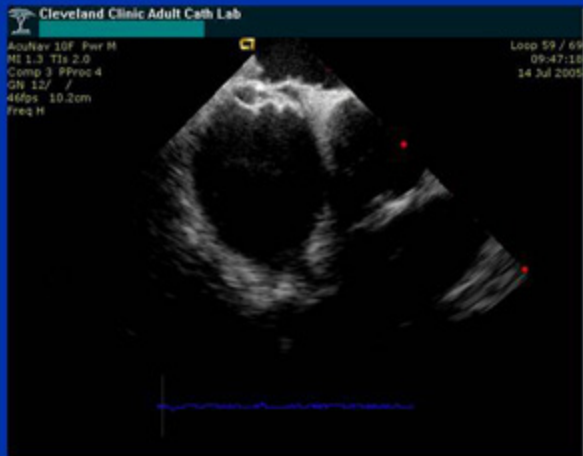
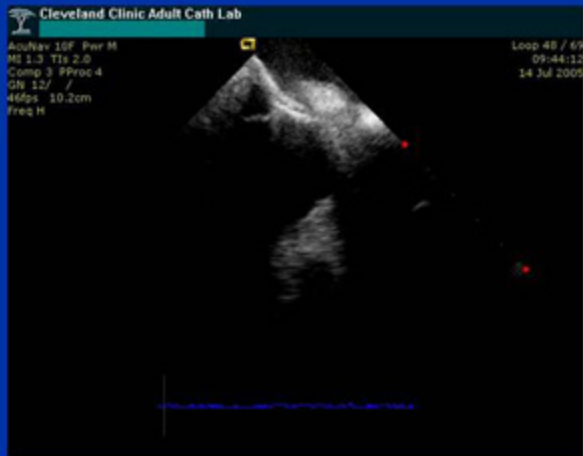
Trans-septal Puncture Technique



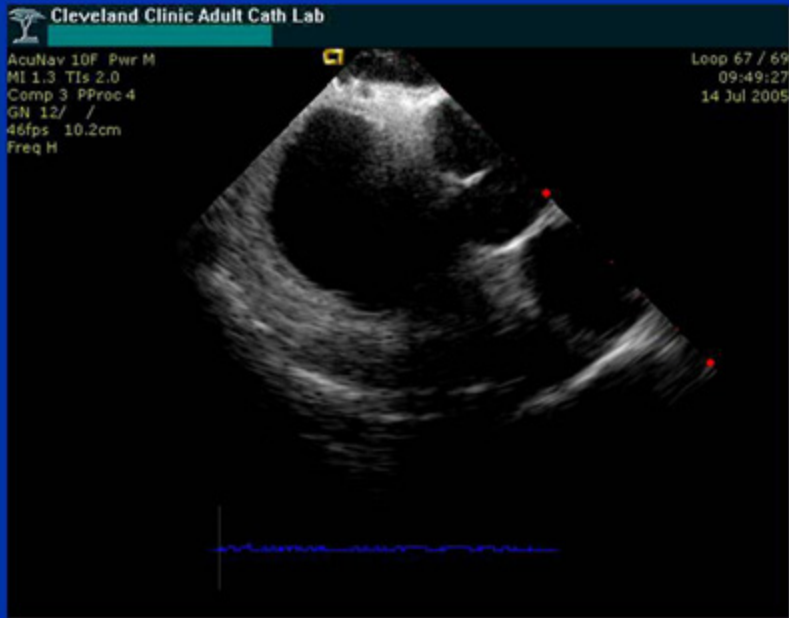
Trans Septal Puncture



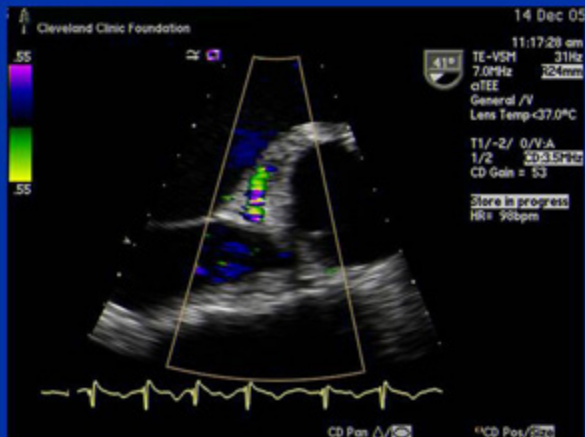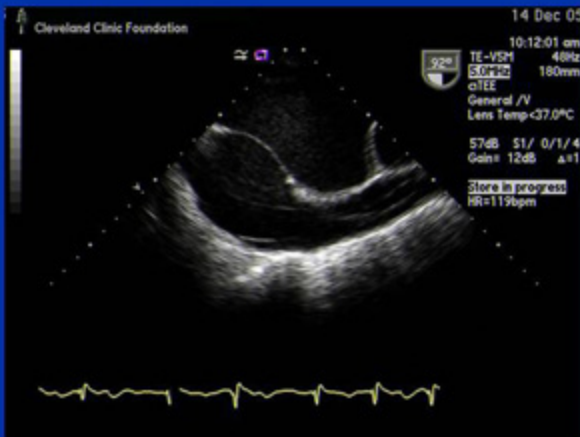
Deployment of Device



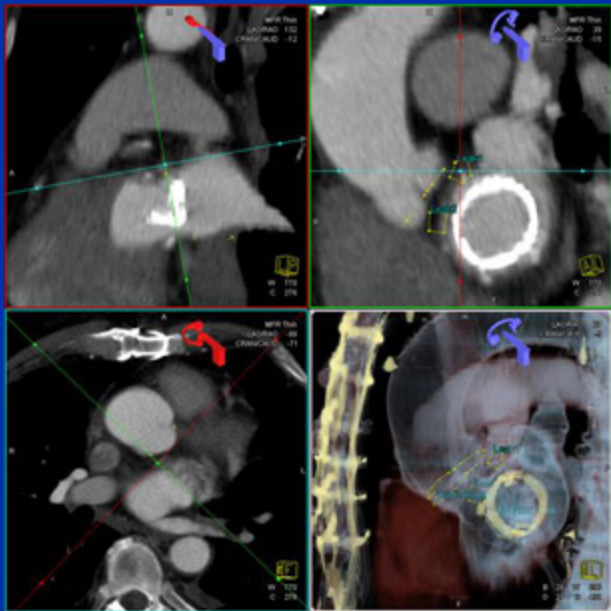
Post Contrast Study



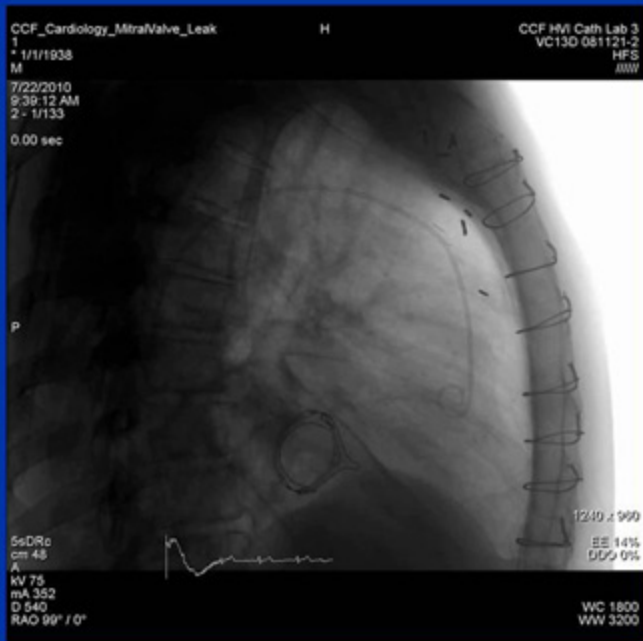
Aortic Puncture



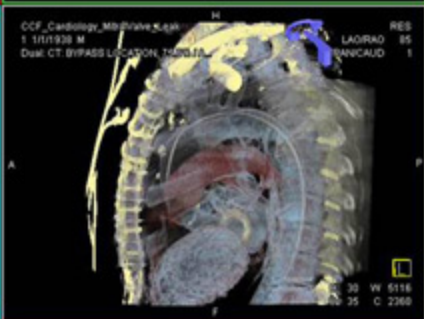
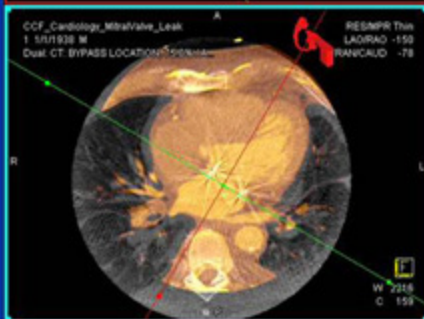
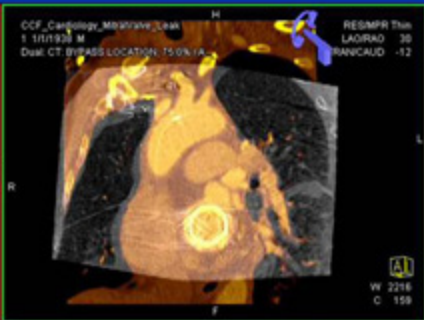
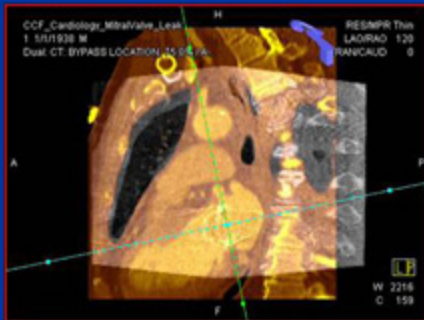
Marking of Area of Interest: Leak



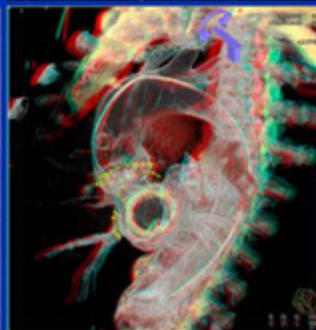
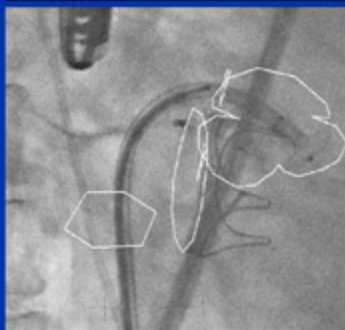
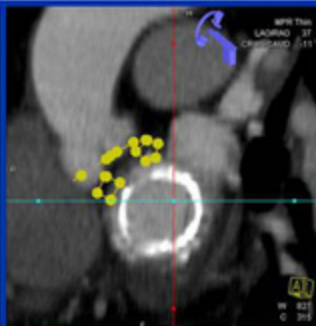
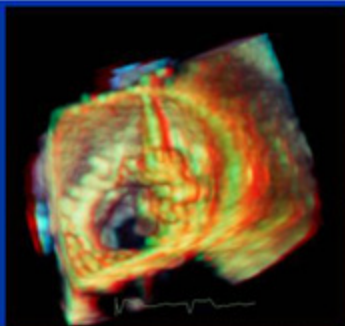
Rotational CT in Cath Lab



Fusion



3D



Crossing the Defect

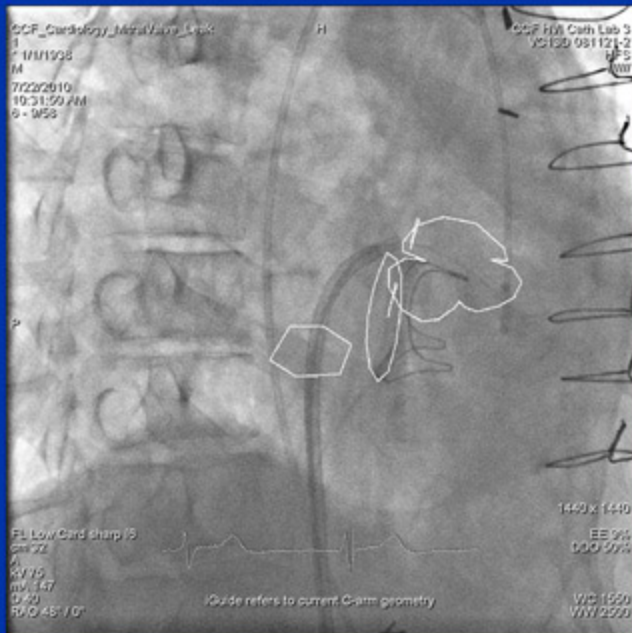
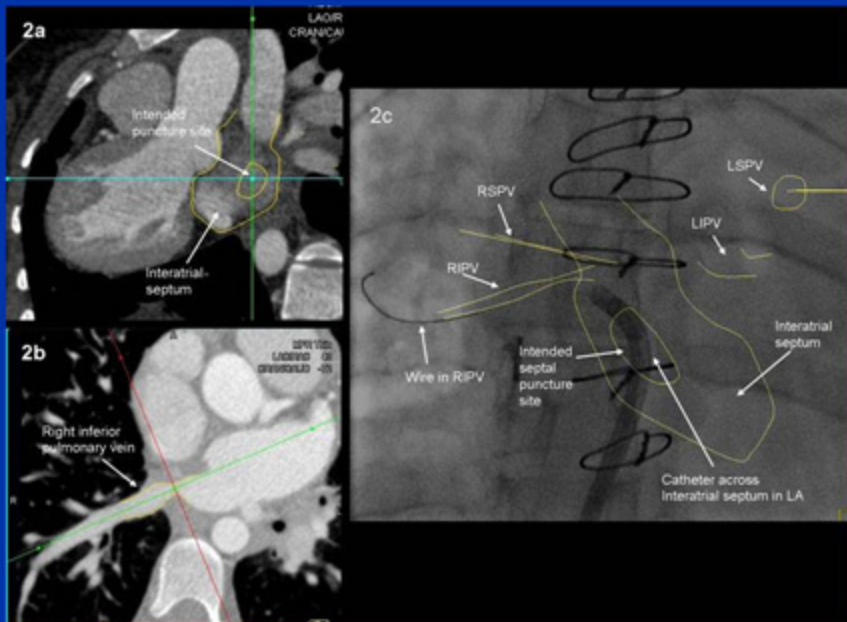
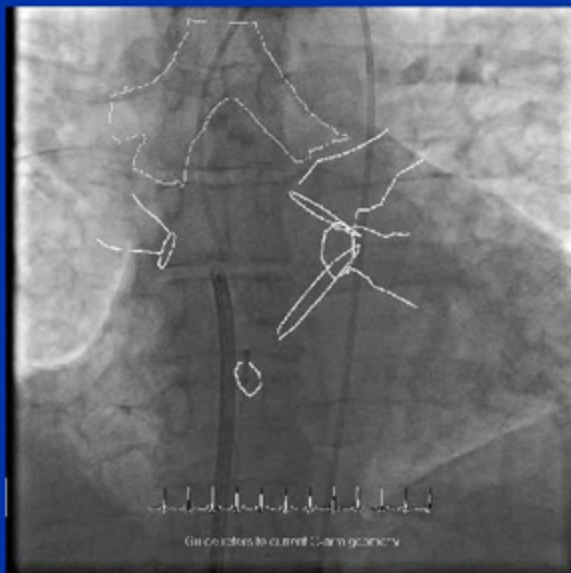

Image Fusion

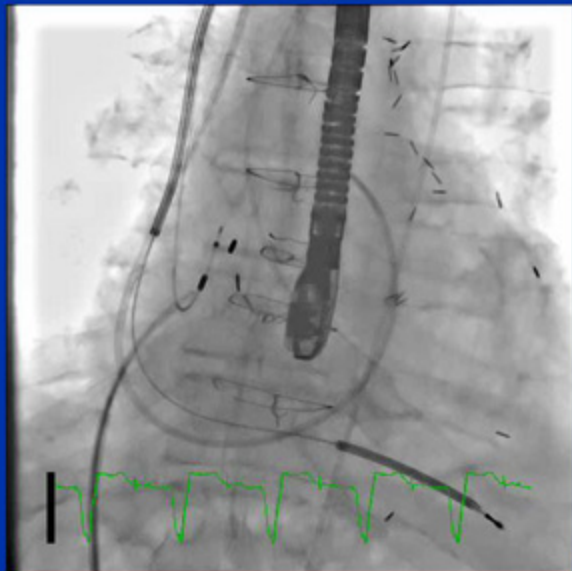


Right Pulmonary Vein Access

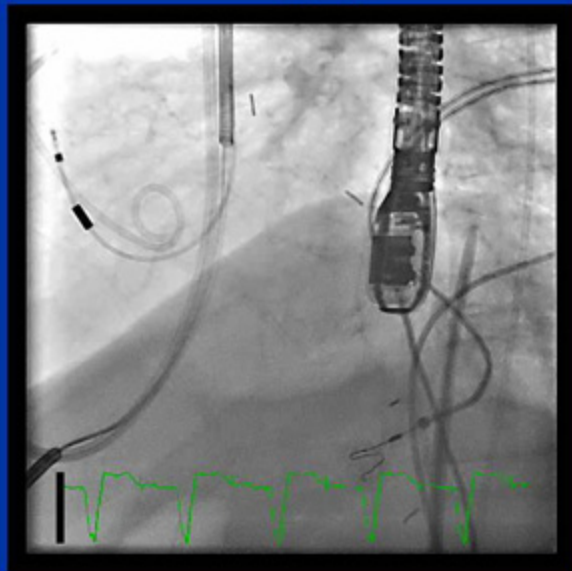


Is it the Correct Site?

AP

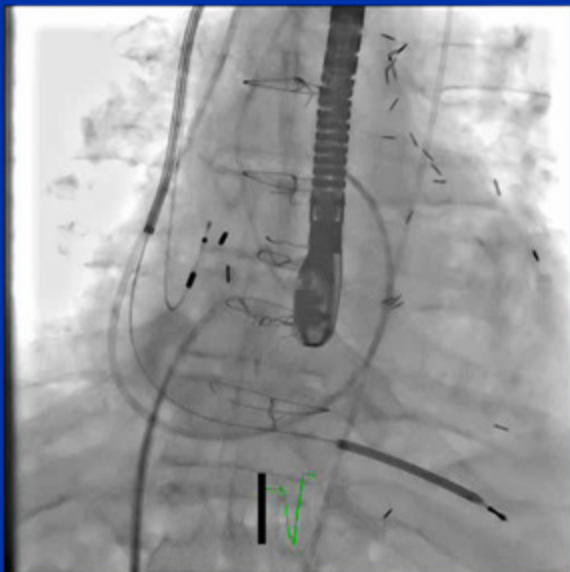

LAT

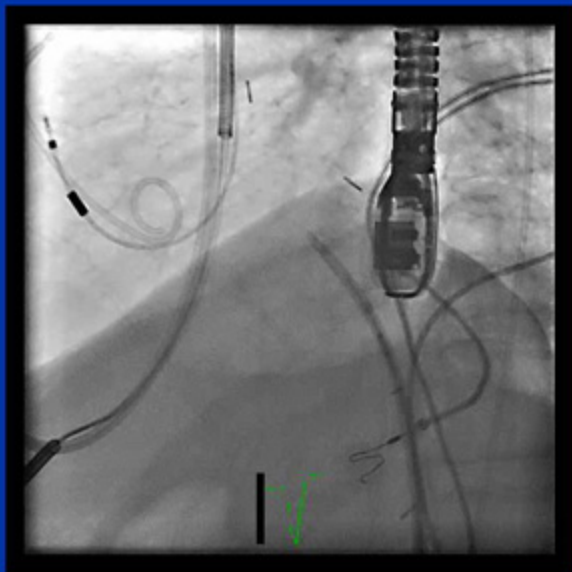


Is this Better?

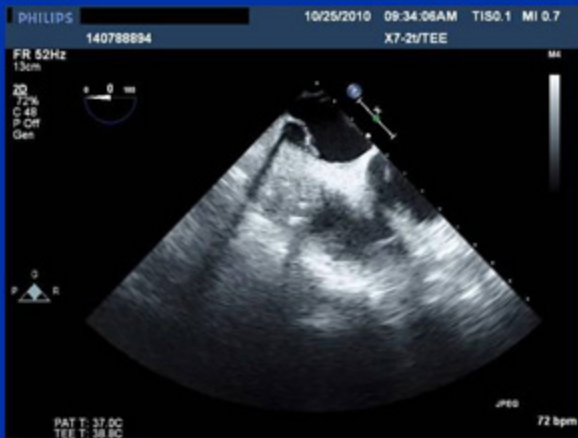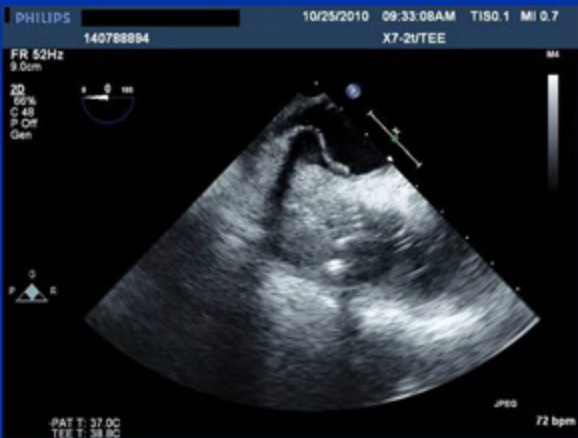AP



LAT



TEE

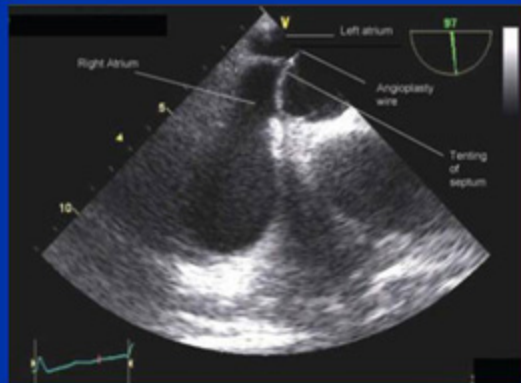

Use of 0.014" wire for LA entry

Use of an Angioplasty Wire to Perforate the Interatrial Septum for a Difficult Transseptal Puncture

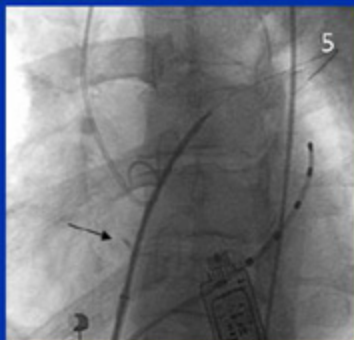
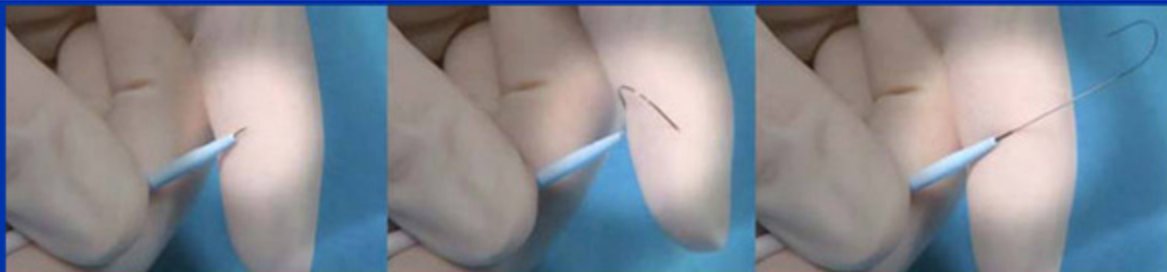SYED Y. AHSAN, M.R.C.P.,* SUE WRIGHT, F.R.C.A.,† PIER D. LAMBIASE, Ph.D.,*
JAMES W. McCREADY, M.R.C.P.,‡ and ANTHONY W. CHOW, M.D., F.R.C.P.*

From the *Department of Cardiovascular Electrophysiology, †Department of Cardiac Anaesthesia and Intensive Care, and ‡University College London Hospitals NHS Trust, The Heart Hospital, London, United Kingdom

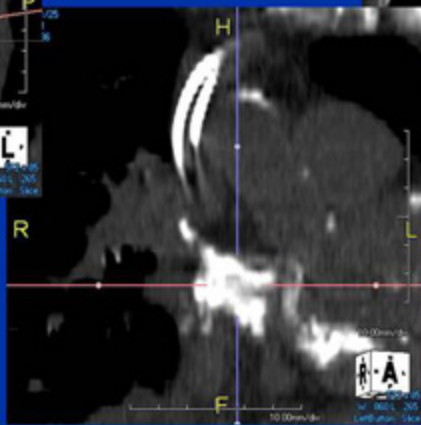
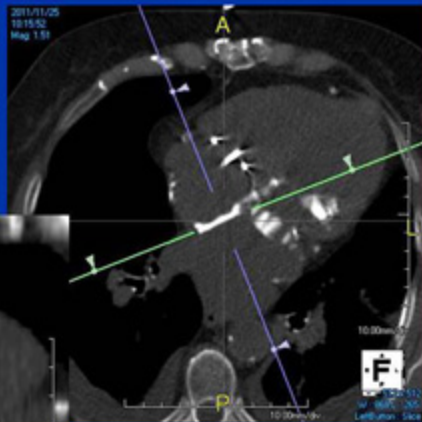
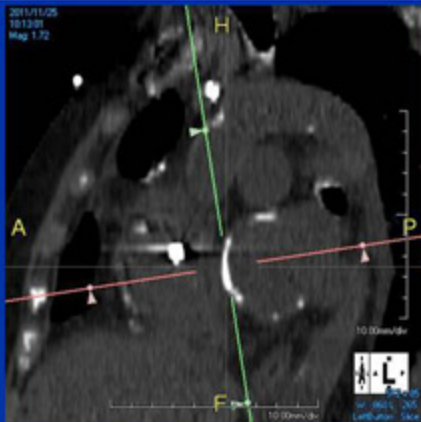


- Shearing of the wire
- Pericardial Entry
- No pressure monitoring

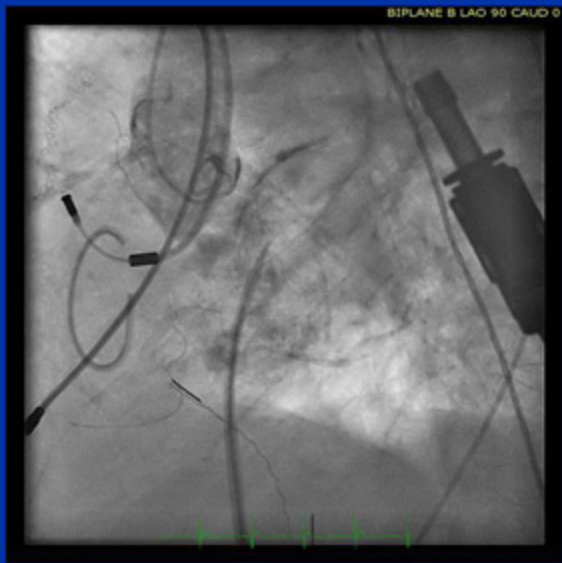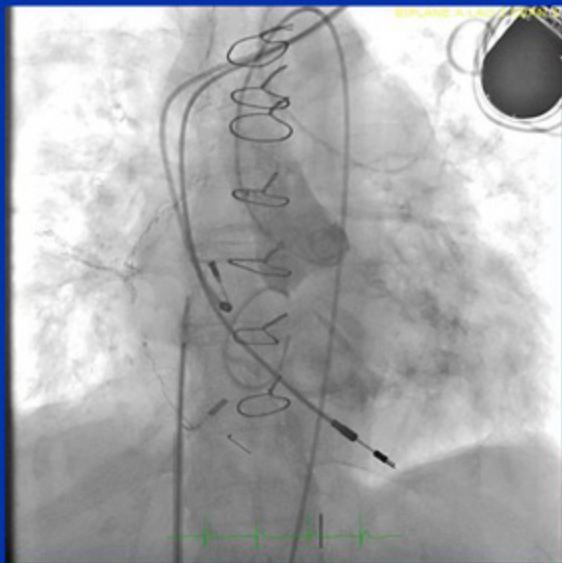
SafeSept™ Needle Wire System



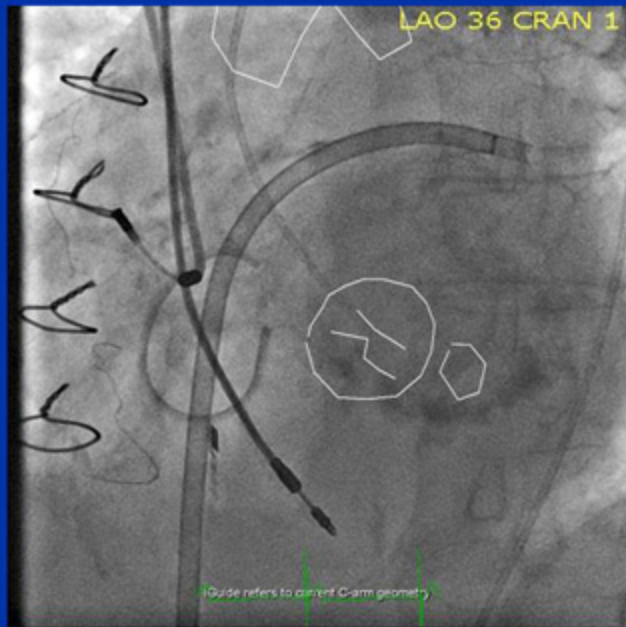
Case of Hostile Septum



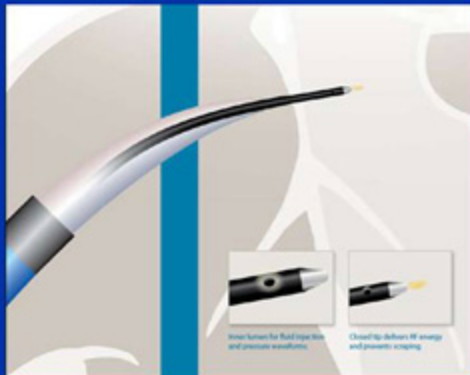Identifying the Location



Successful Puncture at the Right Location



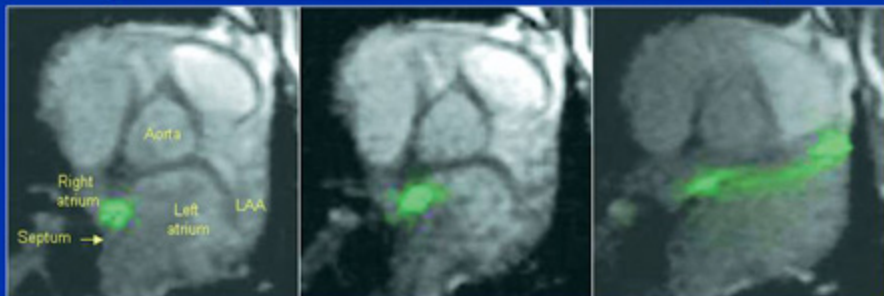

NRG™ RF Transseptal Needle, Baylis Medical



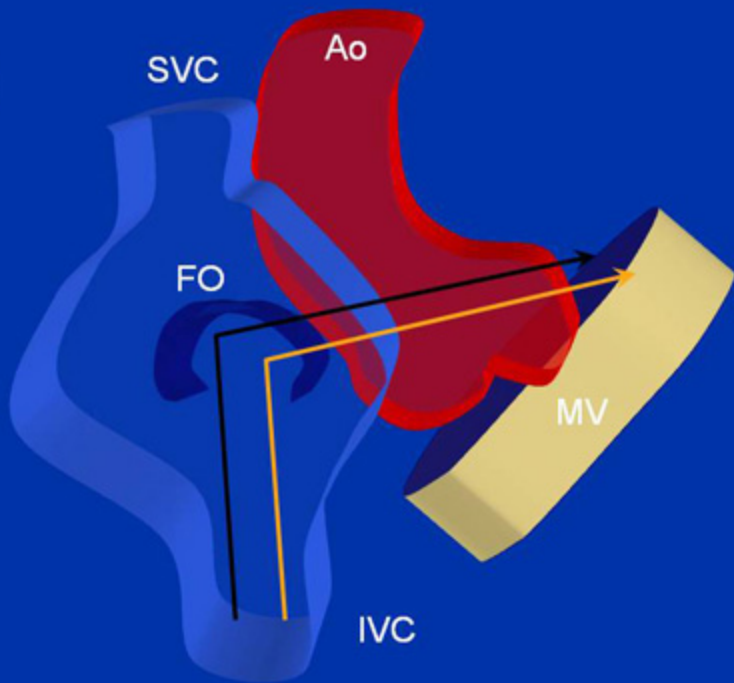
Prospective Comparison

- 241 punctures
- RF delivered in 82%
- Average time
 - 4.8 ± 2.8 min for RF transseptal & 7.5 ± 8.5 min for conventional approach ($p=0.045$)
- Fluoroscopy time
 - 1.8 ± 1.3 min for RF transseptal & 2.9 ± 2.8 min for conventional approach ($p=0.043$)

Laser Catheter



How
Specific?



Safe TSP

- Attention to imaging
- Attention to hemodynamics
- Be patient
- Don't use force!